

DOI: 10.21767/2471-8173.100046

# Diffusion Tensor Imaging and Fibre Tracking Biomarkers of Intramedullary Tumours of Spinal Cord for Predictive Resectability Scoring - An Observational Comparative Study of 48 Cases

Rammohan Vadapalli<sup>1\*</sup>,  
Vijayasaradhi Mudumba<sup>2</sup>  
and Abhinav Sriram  
Vadapalli<sup>3</sup>

- 1 Department of Radiology, Krishna Institute of Medical Sciences, Telangana, India
- 2 Department of Neurosurgery, Nizams Institute of Medical sciences, Telangana, India
- 3 Armed Forces Medical College, Maharashtra, India

## Abstract

**Background:** The aim of this prospective observational comparative study is to evaluate the role of Diffusion Tensor Imaging (DTI) in management of intramedullary spinal cord tumours (IMSCT) for predicting 'safe resectability' to assess subsequent neurological outcomes.

**Methods:** DTI was performed in 65 patients (38 male and 27 females with a mean age of 37.5 years) with IMSCT (intramedullary spinal cord tumours) and conventional contrast enhanced MRI. DTI parameters to predict the margin for tumour resectability included – Medium resolution DTI (Diffusion Tensor Imaging) on a 3T MRI (Philips Ingenia scanner) with following parameters: Axial Plane B values: 0,1000; Number of directions, 15; TR 6248 TE 60; Slice thickness, 2 mm; inter slice gap, 0.5 mm; NSA, 2 and bandwidth 29.8. Tumour matrix fractional anisotropy (FA), tumour cord interface FA and tractograms were, correlated with intraoperative findings and neurological outcomes after surgery and lesions were grouped as – completely resectable, partially resectable and unresectable.

**Results:** There were Significant additional findings using DTI. In this study, 50 were neoplastic (19 ependymomas, 14 astrocytomas, 3 metastases, 4 haemangioblastoma, 5 cavernomas, 5 lipomas); 15 were non neoplastic. DTI was used to classify the lesions as completely resectable (n=18), partially resectable (26) unresectable (6). Two patients were lost for follow up. Spearman's correlation coefficient between DTI prediction of cleavage plane and intraoperative finding of plane was 0.84 (p-value<0.001). Correlation coefficient between DTI prediction of infiltration of tracts and neurological outcome was 0.46 (p-value<0.02). Lesions demonstrated as resectable by DTI had a good outcome (61.1% vs 0.0%; p<0.001); significantly higher number of patients had poor outcome if DTI concluded lesion was nonresectable (19.4% vs 66.7%; p=0.015).

**Conclusion:** This study suggests that DTI plays a significant role in predicting pre-operative, safe resectability of IMSCT.

## Corresponding author:

Rammohan Vadapalli,

✉ rammohanvsv@gmail.com

Senior Consultant Radiologist, MD (PhD),  
Department of Radiology, Krishna Institute  
of Medical Sciences and Consultant  
Radiologist at Vijaya Diagnostics, Himayat  
Nagar, Hyderabad, India.

Tel: 040 27650264

**Citation:** Rammohan V, Mudumba V, Vadapalli AS (2019) Diffusion Tensor Imaging and Fibre Tracking Biomarkers of Intramedullary Tumours of Spinal Cord for Predictive Resectability Scoring - An Observational Comparative Study of 48 Cases. Spine Res. Vol.5 No.1:1

**Received:** January 01, 2019 ; **Accepted:** January 24, 2019; **Published:** January 31, 2019

## Introduction

Surgery and radiotherapeutic treatment effects are limited for intramedullary tumours located primarily in the spinal cord. Management of these lesions depends on their diagnosis using minimal invasive strategies that render sufficient outcome and reduced recurrence. Surgical resection of Intramedullary Spinal

Cord Tumours (IMSCTs) provide neurological and oncological outcome with respect to impact on long-term progression free survival [1]. The primary form of treatment of different intramedullary tumour types including ependymomas, astrocytomas, haemangioblastoma, lipomas and metastases is resection [2,3].

Diagnosis of spinal lesions depends on findings from Magnetic Resonance Imaging (MRI). MRI mediates multiplanar imaging and super contrast resolution with flexible protocols to determine tumour location, delineate lesions and indicate prognostic modalities. As the outcome of resection of intramedullary tumours is poor, a combined approach using Diffusion Tensor Imaging (DTI) and tractography, along with conventional MRI can be used to visualize lesions and their infiltration patterns with enhanced sensitivity [4]. This enables total and safe resection in an identifiable plane of cleavage between the tumour and the spinal cord [5,6]. DTI based fibre tracking detects white matter fibre tracts and pathological alterations [7,8], and along with computation of fractional anisotropy (FA), is sensitive in determining intrinsic abnormalities in a tumour induced cord compression. Hence, DTI, tractography and conventional MRI can be used together in neuroimaging and differential diagnosis of spine tumours, neuro navigation, surgical intervention and follow-up. The aim of this prospective observational comparative study is to evaluate the application of DTI and fibre tracking in the prognosis of IMSCTs to predict 'safe resectability', to reduce the long-term neurologic dysfunction, and to help assess subsequent neurological outcomes.

## Research Methodology

The study included 38 male and 27 female patients with a mean age of 37.5 years. Informed consent was obtained from the patients for this study. DTI along with conventional contrast enhanced MRI was performed in all 65 patients with IMSCTs. Patients excluded from the analysis were those with tumour-like lesions on conventional MRI (n=15) and patients lost to follow up (2 patients, 1 with lipoma, 1 with haemangioblastoma). Hence, effectively 48 patients were analyzed.

Lesions were divided into 3 groups based on the presence of cleavage between the lesions and spinal cord as – completely resectable, partially resectable and unresectable. DTI of lesions was performed with medium resolution on a 3T MRI (Philips Ingenia scanner), with the following imaging parameters: Axial Plane B values: 0, 1000; Number of directions 15; TR 6248 TE 60; Slice thickness 2 mm with 0.5 mm inter slice gap; NSA 2, Matrix 112×112 bandwidth 29.8. Tumour matrix FA and tumour cord interface FA were assessed, and ratios calculated. Tractograms with anatomical image fusion were co-registered for analyses and correlated with intraoperative findings and neurological outcomes following surgery. These results were compared and correlated with intraoperative findings and neurological outcome assessed at the end of the 1-year follow-up.

## Statistical Analysis

Statistical procedures were carried out with software package SPSS 17.0.

Non-parametric Spearman's correlation was performed to determine the following:

- Correlation between the DTI prediction of plane and intraoperative plane;
- Correlation between DTI prediction and intraoperative resectability of the lesion.

DTI interpretation and neurological outcome at the end of 1-year follow-up. Correlation coefficient of  $>0.5$  was considered as good correlation and  $p\text{-value}<0.05$  was significant for all the tests.

## Results

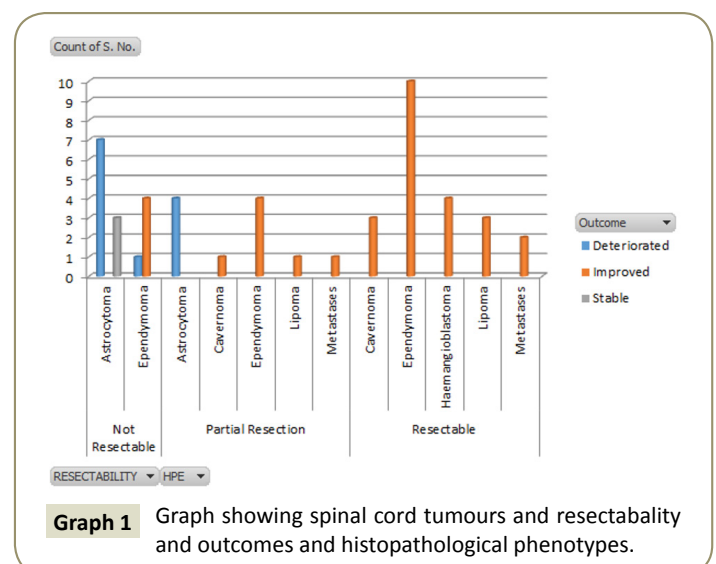
There were 50 patients in this study, (19 ependymomas, 14 astrocytomas, 3 metastases, 4 haemangioblastoma, 5 cavernomas, 5 lipomas). DTI was used to classify the lesions as completely resectable (n=18), partially resectable (26) unresectable (6). 2 patients were lost to follow up and not included in analysis. Tractography based predicted resectability cleavage plane included wide transition zone of reduced FA values at the tumour cord interface, matrix FA and peritumoral FA ratio  $>2$ , and Bo tract infiltration at interface. Spearman's correlation coefficient between DTI prediction of cleavage plane and intraoperative finding of plane was 0.84 ( $p\text{-value}<0.001$ ).

All patients where DTI concluded that the lesion is resectable (including completely and partially resectable groups) had a good outcome (61.1% vs 0.0%;  $p<0.001$ ); significantly higher number of patients had poor outcome if DTI concluded that the lesion was unresectable (19.4% vs 66.7%;  $p=0.015$ ). Correlation coefficient between DTI prediction of infiltration of tracts and neurological outcome (deteriorated or not) was 0.46 ( $p\text{-value}<0.02$ ).

However, in patients where the DTI suggested partial resection, there was no difference in the outcome between unresectable and partially resectable groups respectively (19.4% vs 33.4%;  $p=0.430$ ) (**Graph 1**).

## Discussion

Intramedullary tumours encompass 20% to 30% of all intradural primary spinal tumours that lack clinical symptoms [9]. Although MR imaging is a reliable procedure used to diagnose intermedullary tumours, it can be difficult to distinguish different tumour types. Patients in this study underwent DTI and fibre tractography for 3D visualization of cervical intramedullary spinal tumours in relation to whole matter tracts (**Figure 1A**). Quantitative DTI data was based on diffusivity and anisotropy



of water motion within nerve fibres. The overall results of the study suggest that significant improvement with respect to all variables was observed in the group where DTI had a resectable outcome. An intraoperative diagnosis by biopsy was essential for management of IMSCT where the lesions were partially resected (**Figure 1B**).

The focus of this manuscript is the role of DTI in the management of IMSCT to predict safe resection. The diagnosis of IMSCT is complex due to various factors like infiltrative and non-infiltrative masses, invasivity, intralesional haemorrhage. DTI was used to classify the lesions as completely resectable, partially resectable and unresectable. Axial DTI was assessed to provide detailed information on specific fibre bundles.

Several factors contribute to the clinical features of IMSCTs. DTI of IMSCTs depends upon the lesion types under examination. Tumour matrix fractional anisotropy (FA) and tumour cord interface FA were assessed and ratios for each of the lesion types under examination varied based on the matrix FA and peritumoural FA ratio of each lesion and DTI planes; a resectability score of 1 to 3 was developed (0 or 1=not resectable; 2=partial resection; 3=resectable). DTI interpretation and neurological outcome were determined at the end of 1 year follow up. Patients in whom DTI concluded that the lesion was resectable, had a good outcome ( $p<0.001$ ). Poor outcome was observed in patients in whom DTI concluded that the tumour was not resectable ( $p=0.015$ ). No difference in outcome was observed in patients in whom DTI

suggested partial resection. Using tractography was useful in pre-operative prediction of the nature of lesions and in delineating surgical intervention (**Graph 2**).

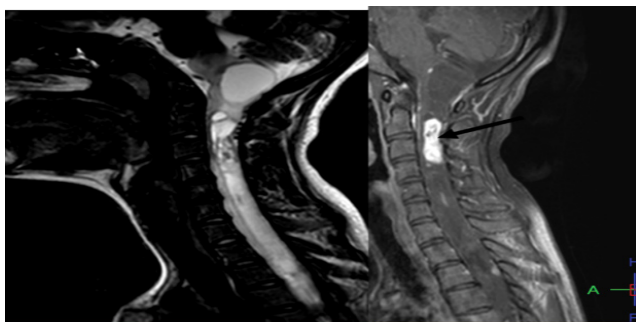
## Pathophysiology

Tumour resection is guided by multiple factors including tumour location, size and pathology, invasion mode and operative exposure.

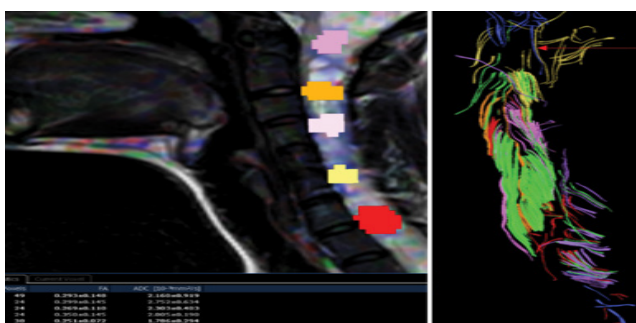
## Astrocytoma

Astrocytoma is a rare central nervous system neoplasm. It is of eccentric location within the spinal cord, exophytic nature, extramedullary with poorly defined margins (**Figure 2A**) [10,11]. Pathologically astrocytomas grow at an enhanced rate compared to ependymomas and feature aggravated prognosis. Unlike cord ependymomas, a cleavage plane is absent in intramedullary spinal astrocytomas (**Figure 2B**). Malignant tumours produce rapid neurological deterioration.

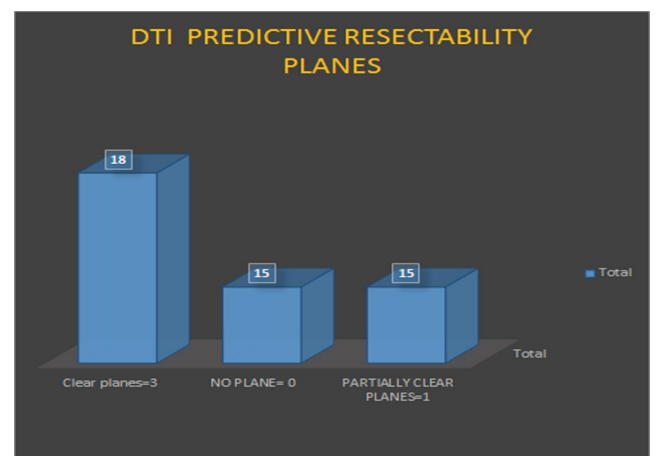
Our DTI and fibre tracking findings add a new dimension of pre-operative estimation of surgical plane in intramedullary neoplasms. Four criteria were used to decide the presence of a cleavage plane between the tumour and normal adjacent cord, allowing resectability. These features were graded as resectability score of 0 or 1 for astrocytomas (**Graph 3**).



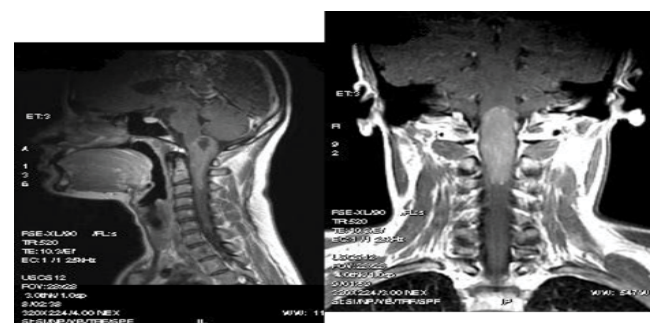
**Figure 1A** Cervical spinal cord intramedullary astrocytoma: Sagittal T2 and T1 pre and post contrast showing enhancing lesion within the cervical cord opposite C4.



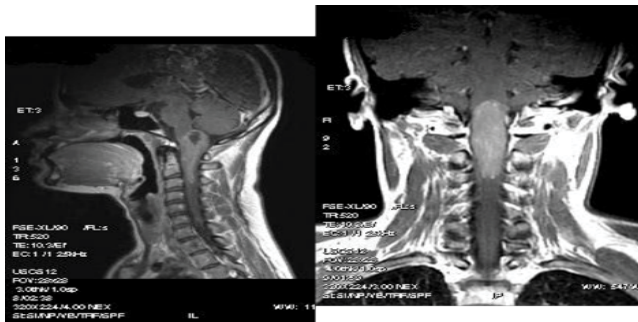
**Figure 1B** Intramedullary astrocytoma tract infiltration at cord tumour interface at both poles. No planes of cleavage. Resectability score of 0.



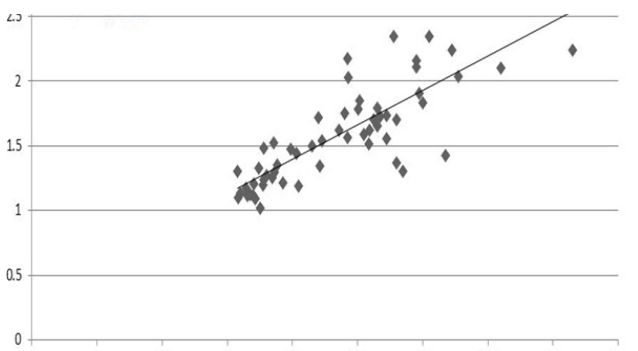
**Graph 2** DTI (Diffusion Tensor Imaging) and fiber tracking based Predictive resectability.



**Figure 2A** Post contrast T1 sagittal and coronal images showing cervical-medullary astrocytoma with exophytic component.



**Figure 2B** DTI and fibre tracking of cervical cord showing FA maps of the tumour (with regions of interest represented by values between 0 to 1) and tractograms at the cord tumour interface showing astrocytoma with wide transition zone of reduced FA values. Tract infiltration at inferior pole. No resectability planes with score of 0. FA, fractional anisotropy



**Graph 3** Matrix FA and peri tumoral FA ratio: Tractography planes vs. intra operative surgical findings in astrocytomas.  
**Vertical axis:** Matrix FA and peritumoral FA ratio  
**Horizontal axis:** Degree of resectability.

- 1) High FA values with a ring pattern between the tumour and adjacent normal cord - this is best seen on colour coded FA maps and is indicative of a good cleavage plane. It is absent in astrocytoma and suggestive of their infiltrative nature (Table 1).
- 2) Transition zone of FA value in the peritumoural zone where the tumour matrix shows reduced FA compared to the normal cord and this reduction of FA shows a narrow transition zone if the tumour is non-infiltrating or encapsulated. Narrow transition zone is seen in non-infiltrative tumours like haemangioblastoma, ependymomas, metastases, lipoma and cavernoma. The transition zone is wide in astrocytomas and high grade ependymomas.
- 3) Matrix FA and peritumoural FA ratio is higher than 2 in well-encapsulated non-infiltrating tumours, and significantly less than 1 or equal to one in high grade infiltrating tumours. It can range between 1-1.5 in intermediate grade lesions. Perifocal edema also contributes to minimal reduction of FA values in the peritumoural zone (Figure 3).

- 4) Fibre tract infiltration at the cord tumour interface are present in infiltrating tumours. Fibre tracts show displacement or splaying around the lesion or capping in a non-infiltrating lesion. Infiltration is absent in non-infiltrating tumours.

## Ependymomas

Ependymomas are spinal lesions common in adult in the cervical region of the spine. Its clinical features include centrally located lesions characterized by a cleavage plane from the spinal cord due to concentric growth. Ependymomas vary from astrocytomas in their size, location, margin, signal intensity, contrast enhancement, presence of syringo hydromyelia, tumoural cyst, non-tumoural cyst, and haemorrhage [12,13]. Focal intense homogeneous contrast enhancement is associated with frequent and prominent cysts (intra tumoural and polar) [14] (Figure 4A).

DTI and fibre tracking features of ependymomas include the following and were graded as resectability score of 3.

- 1) High FA values with a ring pattern between the tumour and adjacent normal cord (High FA ring sign) suggestive of their non-infiltrative nature (Table 1).
- 2) Transition zone of FA value in the peritumoural zone is narrow and suggestive of well-defined cord tumour interface in myxopapillary ependymoma (Figure 4B).
- 3) Matrix FA and peritumoural FA ratio ranges around 2 or more than 2 in well-defined non-infiltrative neoplasms like ependymomas (Table 1).
- 4) Fibre tract infiltration at the cord tumour interface: absent in ependymomas. Tracts appear capped and splayed around the tumour (Figures 5A-5C).

## Haemangioblastomas

Haemangioblastomas are usually benign vascularized intramedullary lesions found in the posterior fossa and spinal cord that are linked to Von Hippel-Lindau Disease (VHL). A haemangioblastoma larger than 24 mm indicates vascular flow voids on MR images [15]. Symptomatic small haemangioblastomas demonstrate a relatively large associated syrinx while asymptomatic haemangioblastomas contain peritumoural edema.

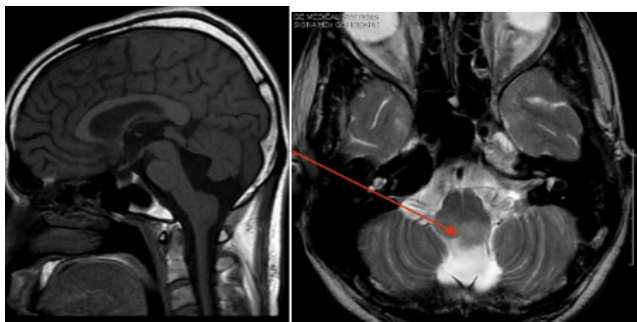
MR features of spinal haemangioblastoma depend on the size of the tumour [16]. Small (10 mm or less) haemangioblastomas are mostly isointense on T1-weighted images and hyperintense on T2-weighted images and show homogeneous enhancement, whereas larger ones tend to be hypointense or mixed hypo- and isointense on T1-weighted images and heterogeneous on T2-weighted images and tend to show heterogeneous enhancement. DTI and fibre tracking features of haemangioblastomas include the following and recorded features were graded as resectability score of 3 (Figure 6).

**Figure 6** Haemangioblastoma: cervical cord matrix FA (fractional anisotropy) and peritumoural FA ratio ranges around 1.8 to 2 or more than 2 in these well-defined non-infiltrative neoplasms like Haemangioblastoma. Fibre tract infiltration at the cord tumour interface is absent. Tracts appear capped and splayed around the tumour including the solid and cystic components.

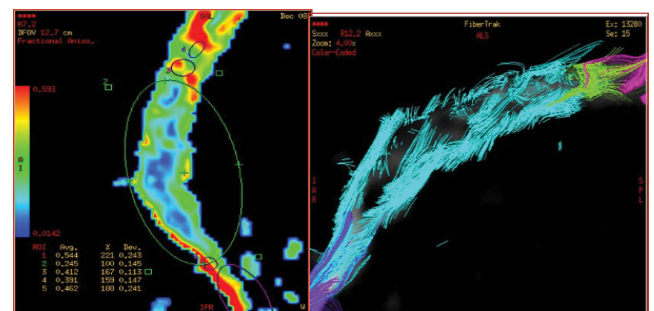


**Table 1** DTI and Fiber tracking Features for characterization of intramedullary spinal cord tumours.

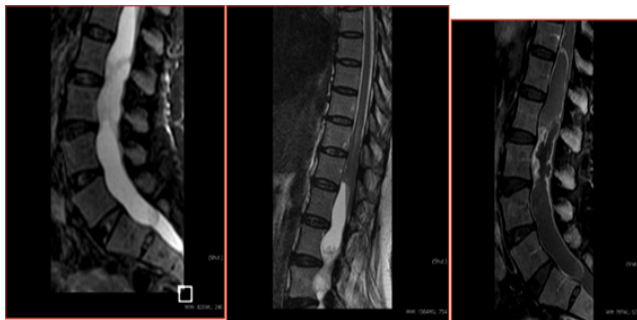
DTI Characteristics	Astrocytoma	Ependymoma	Haemangioblastoma	Lipoma	Cavernoma	Metastases
High FA Rind sign	Absent	Present	Present	Present		Partial due to edema
FA value transition at cord tumour interface	wide	Narrow	Narrow	Narrow	Narrow	Narrow to wide due to edema
Matrix FA and peri tumoral FA ratio	1 or <1	>2	>2	>2	>2	1.5 to 2 due to edema
DTI planes	Not clear	clear at pores and ventrally	clear at pores and ventrally	clear	clear planes	clear planes if edema is minimal
Resectability score	0= not Resectable or 1=biopsy	3=complete Resectable	=3 Resectable	=3	=3 Resectable	=3/=2 if edema is present



**Figure 3** Cervico medullary astrocytoma with exophytic component and tract infiltration at cord tumour interface at both poles. No resectability or cleavage planes. Resectability score of 0.

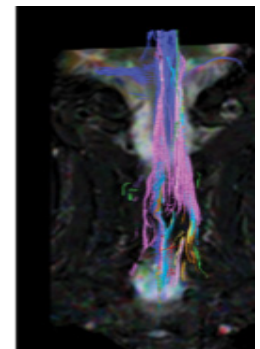
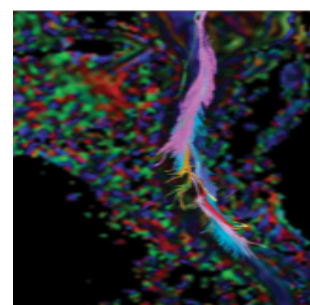
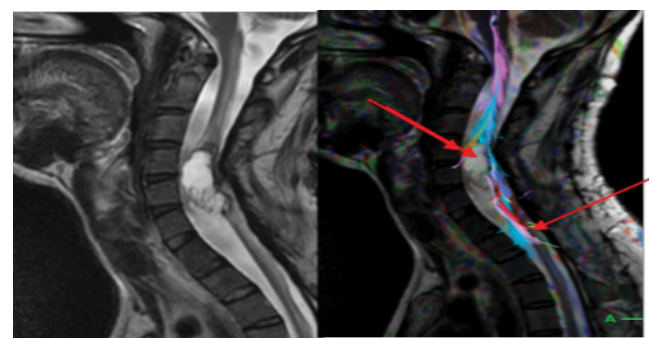


**Figure 4B** DTI study with tractograms co-registered with T2 sagittal image: Myxopapillary ependymoma of cauda equina with intact tracts at the cord tumour interface suggestive of non-infiltrative margins with Matrix FA and Peritumoural FA ratio of >2. Resectability score of 3.

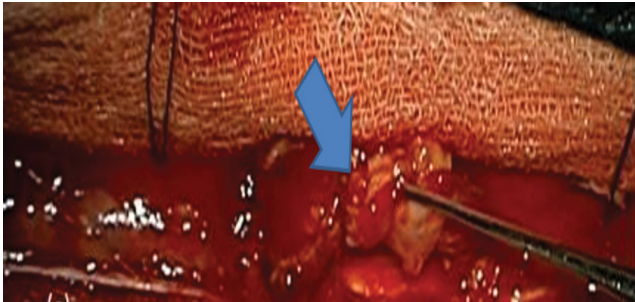


**Figure 4A** Myxopapillary Ependymoma: T1, T2 and post contrast sagittal views showing the enhancing intramedullary conus neoplasm.

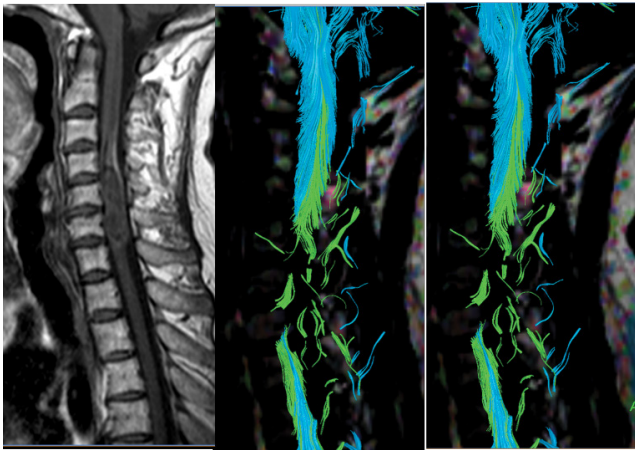
- 1) High FA values with a rind pattern between the tumour and adjacent normal cord (High FA rind sign) and suggestive of their non-infiltrative nature.
- 2) Transition zone of FA value in the peritumoural zone: Narrow suggestive of well-defined cord tumour interface. Pial surface flow voids or serpiginous vessels at the periphery with edema may lower the FA values minimally in the peritumoural zone.
- 3) Matrix FA and peritumoural FA ratio ranges around 1.8 to 2 or more than 2 in these well-defined non-infiltrative neoplasms like haemangioblastoma.
- 4) Fibre tract infiltration at the cord tumour interface is absent in haemangioblastoma. Tracts appear capped and



**Figure 5A** Ependymoma cervical cord with exophytic component and matrix haemorrhage (B) DTI tractograms show no ventral cleavage planes. No tract infiltration at normal cord and tumour interface at the superior and inferior pole. Resectability score of 3.



**Figure 5C** Intraoperative image of cervical cord ependymoma showing clear planes at the poles and facilitating complete resection.



**Figure 6** Haemangioblastoma: cervical cord matrix FA (fractional anisotropy) and peritumoural FA ratio ranges around 1.8 to 2 or more than 2 in these well-defined non-infiltrative neoplasms like Haemangioblastoma. Fibre tract infiltration at the cord tumour interface is absent. Tracts appear capped and splayed around the tumour including the solid and cystic components.

splayed around the tumour including the solid and cystic components.

## Lipoma

Lipoma are spinal intramedullary rare lesions and include about<1% of all spinal masses and 2% of intramedullary tumours. Spinal lipoma is present in the cervico-thoracic region and displace dorsal neural roots laterally [17,18]. MRI with multiplanar imaging demonstrate fat and spinal lesions [19,20]. On the basis of high proportion of fat that confers a short T1 relaxation time, we made a diagnosis of lipomas that are hyperintense on T1-weighted images. Benign lipomas have relaxation parameters similar to those of subcutaneous fat.

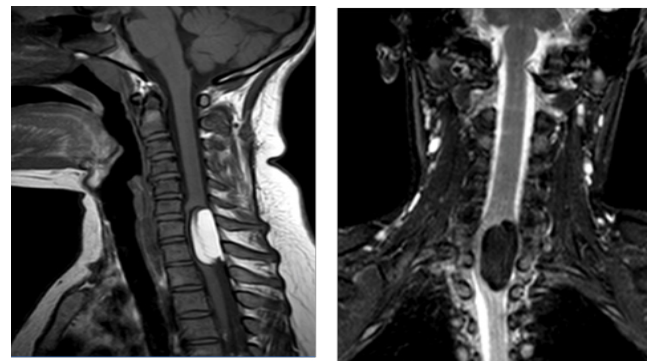
DTI and fibre tracking features of lipoma include the following and features were graded as a resectability score of 3.

- 1) High FA values with a ring pattern between the tumour and adjacent normal cord (High FA ring sign) present in lipoma are suggestive of their non-infiltrative nature.


- 2) Transition zone of FA value in the peritumoural zone is narrow and suggestive of well-defined cord tumour interface. Chemical shift induced artifacts in peritumoural zone can make cord tumour interface indistinct especially on spin echo sequences. Hence, conventional T1 post contrast T1 weighted fat suppressed MR images are used to co-register with FA maps and fibre tractograms.
- 3) Matrix FA and peritumoural FA ratio are more than 2 in these well-defined non-infiltrative lipomatous neoplasms.
- 4) Fibre tract infiltration at the cord tumour interface are absent in lipoma. The tracts appear capped and splayed around the tumour. Tumour cord adherence with exophytic extra medullary component can exist with focal fibre infiltration at the site of adherence (**Figures 7A-7C**).

## Intramedullary Spinal Cavernoma (ISC)

Intramedullary spinal cavernoma (ISC) is a rare vascular disease of an enlarged mass of sinusoidal vessels in the lumbosacral region. It accounts for 5%-12% of all spinal vascular pathologies [21,22]. Neurological deficits and several other symptoms due to acute macro haemorrhage forming a space occupying lesion are

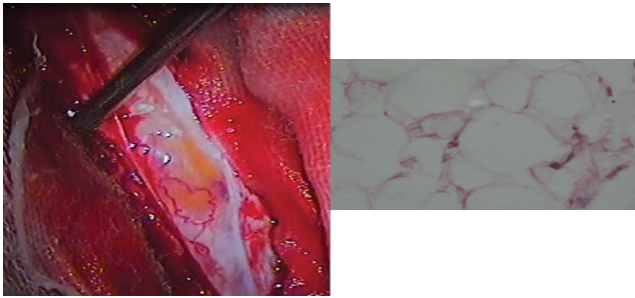


**Figure 7A** T1 sagittal and T2 coronal fat suppression images of intradural lipoma of cervical cord with cord adherence and intra medullary extension.



**Figure 7B** Lipoma with cord adherence and splaying of Lateral Spinothalamic tracts and Posterior columns with infiltration at 5'0 clock position at the site of adherence. No tract infiltration otherwise. Respectability score of 2.





**Figure 7C** Intraoperative image showing subpial location of lipoma, with no plane of cleavage at the cord lipoma interface and histopathology confirmed lipoma. Near total resection was performed.

associated with ISC. Edema of the spinal cord is associated with recurrent haemorrhage.

DTI and fibre tracking features of cavernoma (**Figure 8**)

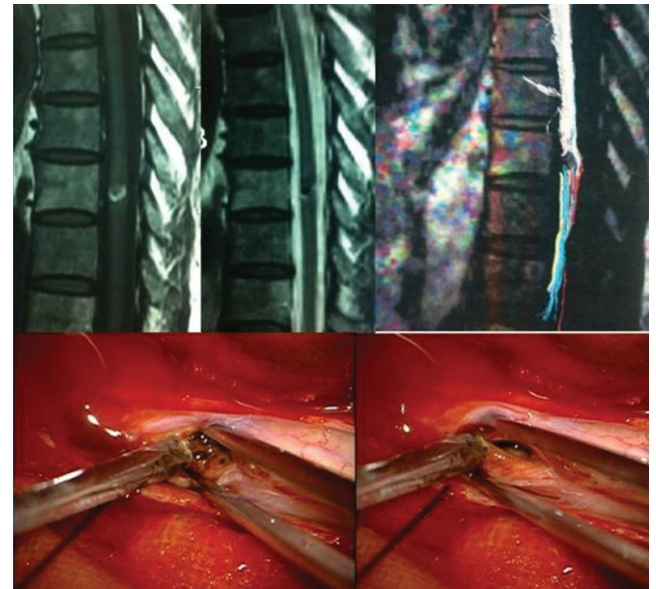
- 1) High FA values with a rind pattern between the tumour and adjacent normal cord (High FA rind sign) are present in cavernoma and suggestive of their non-infiltrative nature.
- 2) Transition zone of FA value in the peritumoural zone is narrow and suggestive of well-defined cord tumour interface. Hemosiderin induced blooming in peritumoural zone can make cord tumour interface indistinct especially on Gradient Echo sequences. Hence, conventional T1 and post contrast T1 weighted MR images are used to co-register with FA maps and fibre tractograms.
- 3) Matrix FA and peritumoural FA ratio are more than 2 in these well-defined non-infiltrative lipomatous neoplasms (**Figure 9**).
- 4) Fibre tract infiltration at the cord tumour interface is absent in cavernoma. Here, the tracts appear capped and splayed around the tumour.

## Metastases in the cord

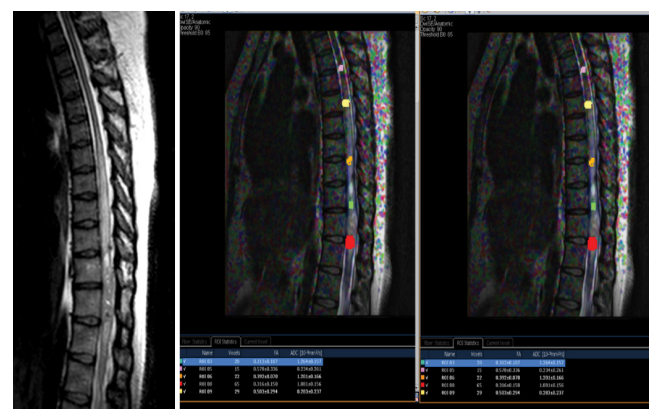
Intramedullary spinal metastases rarely occur in about 1% of autopsied patients with poor prognosis [23,24]. Symptomatically, the disease is indicated by severe pain, loss of neurological function, paralysis, sensory loss and compressed neurologic spinal nerves [25-27].

DTI and fibre tracking features include the following and the features were graded as resectability score of 3. . (**Table 1**).

- 1) High FA values with a rind pattern between the tumour and adjacent normal cord (High FA rind sign) present in metastases are suggestive of their non-infiltrative nature.
- 2) Transition zone of FA value in the peritumoural zone is narrow and suggestive of well-defined cord tumour interface.
- 3) Matrix FA and peritumoural FA ratio ranges from 1.2 to 1.5 in well-defined non-infiltrative neoplasms like metastases. Due to significant perifocal edema, reduced FA values are noted (**Figure 9**).
- 4) Fibre tract infiltration at the cord tumour interface is absent in metastases. Tracts appear capped and splayed and



**Figure 8** Cavernoma of Dorsal cord: DTI fibre tractograms overlaid on T2 anatomical images showing splaying and displacement of fibres draping around tumour with no infiltration at cord tumour interfaces at both poles. Transition zone of FA value in the peritumoural zone is narrow and suggestive of well-defined cord tumour interface. Hemosiderin induced blooming in peritumoural zone can make cord tumour interface indistinct especially on Gradient Echo sequences. Hence, conventional T1 and post contrast T1 weighted MR images are used to co-register with FA maps and fibre tractograms. FA, fractional anisotropy.



**Figure 9** Metastases from renal cell carcinoma with perifocal edema: Fibre tract infiltration at the cord tumour interface is absent in metastases. Tracts appear capped and splayed and displaced around the tumour, but due to perifocal cord edema the FA values and density of fibres get reduced. Matrix FA and peritumoural FA ratio ranges from 1.2 to 1.5 in well-defined non-infiltrative neoplasms like metastases. FA, fractional anisotropy.

displaced around the tumour, but due to perifocal cord edema the tracts get reduced.

DTI and fibre tracking for spinal cord intramedullary tumour characterization is an effective tool as an adjunct to conventional

MR imaging to accurately predict the infiltrative versus non-infiltrative pattern of the lesion and hence resectability scoring which facilitate neurological outcome. Most infiltrative nature of the tumour is seen for astrocytomas which are not usually resectable due to their infiltrative nature, now demonstrated by the tract infiltration DTI, with no cleavage plane available for the surgeon between the tumour and the adjacent cord.

## Conclusion

This study suggests that DTI is useful in predicting the safe resectability of IMSCT. Gross resection in ependymomas, haemangioblastomas, cavernomas, and metastases compared to astrocytomas was significant, suggesting good neurological outcome. Splaying and displacement of fibre tracts accurately determine a discrete margin of resection of the tumour. However, regions of infiltration of the fibre tracts suggest an absent cleavage plane and hence unresectable, where image guided biopsy may be more advisable. The goal through the use of DTI and fibre tractography modalities is complete tumour excision without

affecting the neurologic functions and can potentially direct local therapies for tumour infiltration.

## Limitations

The study sample was small and larger sample sizes would enhance clinical, functional and oncological outcome of patients. Follow up study and neurological assessment of intramedullary lesions may aid in minimal surgical morbidity following resection.

## Clinical Utility

Due to the sensitivity of both modalities, DTI and fibre tracking can be employed to characterize intramedullary tumours as an adjunct to conventional MR imaging to facilitate differential diagnosis and enable resectability scoring thus improving the surgical outcomes.

## Acknowledgements

The authors would like to thank Aparna Jagannathan, PhD for providing support for the writing and proof reading of manuscript.

## References

- Virdi G (2017) Intramedullary spinal cord tumours: A review of current insights and future strategies. *Spine Res* 3: 13.
- Weinstein GM, Arkun K, Kryzanski J, Lanfranchi M, Gupta GK, et al. (2016) Spinal intradural extramedullary ependymoma with astrocytoma component: a case report and review of the literature. *Case Rep Pathol* 2016: 3534791.
- Ottenhausen M, Ntoulis G, Bodhinayake I, Ruppert FH, Schreiber S, et al. (2018) Intradural spinal tumors in adults-update on management and outcome. *Neurosurg Rev* 1-18.
- Setzer M, Murtagh RD, Murtagh FR, Eleraky M, Jain S, et al. (2010) Diffusion tensor imaging tractography in patients with intramedullary tumors: comparison with intraoperative findings and value for prediction of tumor resectability. *J Neurosurg Spine*. 13: 371-380.
- Rashad S, Elwany A, Farhoud A (2018) Surgery for spinal intramedullary tumors: technique outcome and factors affecting resectability. *Neurosurg Rev* 41: 503-511.
- Montano N, Papacci F, Trevisi G, Fernandez E (2017) Factors affecting functional outcome in patients with intramedullary spinal cord tumors: results from a literature analysis. *Acta Neurol Belg* 117: 277-282.
- Choudhri AF, Whitehead MT, Klimo P, Montgomery BK, Boop FA (2014) Diffusion tensor imaging to guide surgical planning in intramedullary spinal cord tumors in children. *Neuroradiol* 56: 169-174.
- Landi A, Palmarini V, D'Elia A, Marotta N, Salvati M, et al. (2016) Magnetic resonance diffusion tensor imaging and fiber-tracking diffusion tensor tractography in the management of spinal astrocytomas. *World J Clin Cases* 4: 1-4.
- Abul-Kasim K, Thurnher MM, McKeever P, Sundgren PC (2008) Intradural spinal tumors: Current classification and MRI features. *Neuroradiol* 50: 301-314.
- Epstein FJ, Farmer JP, Freed D (1992) Adult intramedullary astrocytomas of the spinal cord. *J Neurosurg* 77: 355-359.
- Koeller KK, Rosenblum RS, Morrison AL (2000) Neoplasms of the spinal cord and filum terminale: radiologic-pathologic correlation. *Radiographics* 20: 1721-1749.
- Kim DH, Kim JH, Choi SH, Sohn CH, Yun TJ, et al. (2014) Differentiation between Intramedullary spinal ependymoma and astrocytoma: comparative MRI analysis. *Clin Radiol* 69: 29-35.
- Seo HS, Kim JH, Lee DH, Lee YH, Suh SI, et al. (2010) Non-enhancing intramedullary astrocytomas and other MR imaging features: a retrospective study and systematic review. *AJNR Am J Neuroradiol* 31: 498-503.
- Kahan H, Sklar EM, Post MJ, Bruce JH (1996) MR characteristics of histopathologic subtypes of spinal ependymoma. *AJNR Am J Neuroradiol* 17: 143-150.
- Yu JS, Short MP, Schumacher J, Chapman PH, Harsh GR (1994) Intramedullary hemorrhage in spinal cord hemangioblastoma. *J Neurosurg* 81: 937-940.
- Baker KB, Moran CJ, Wippold FJ, Smirniotopoulos JG, Rodriguez FJ, et al. (2000) MR imaging of spinal hemangioblastoma. *AJR Am J Roentgenol* 174: 377-382.
- McLone DG, Naidich TP (1986) Laser resection of fifty spinal lipomas. *Neuros* 18: 611-615.
- Naidich TP, Zimmerman RA, McLone DG, Raybaud CA, Altman NR, et al. (1996) Congenital anomalies of the spine and spinal cord. Magnetic resonance imaging of the brain and spine. (2<sup>nd</sup> edn) Lippincott-Raven Philadelphia, USA.
- Lee RR (2000) MR imaging of intradural tumors of the cervical spine. *Magn Reson Imaging Clin N Am* 8: 529-540.
- Patwardhan V, Patanakar T, Patkar D, Armao D, Mukherji SK (2000) MR imaging findings of intramedullary lipomas. *AJR Am J Roentgenol* 174: 1792-1793.
- Grasso G, Alafaci C, Granata F, Cutugno M, Salpietro FM, et al. (2014) Thoracic spinal cord angioma: a case report and review of the literature. *J Med Case Rep* 8: 271.
- Reitz M, Burkhardt T, Vettorazzi E, Raimund F, Fritzsche E, et al. (2015) Intramedullary spinal cavernoma: clinical presentation,



- microsurgical approach, and long-term outcome in a cohort of 48 patients. *Neurosurg Focus* 39: E19.
- 23 Mostardi PM, Diehn FE, Rykken JB, Eckel LJ, Schwartz KM, et al. (2014) Intramedullary spinal cord metastases: visibility on PET and correlation with MRI features. *AJNR Am J Neuroradiol* 35: 196-201.
- 24 Wilson DA, Fusco DJ, Uschold TD, Spetzler RF, Chang SW (2012) Survival and functional outcome after surgical resection of intramedullary spinal cord metastases. *World Neurosurg* 77: 370-374.
- 25 Dam-Hieu P, Seizeur R, Mineo JF, Metges JP, Meriot P, et al. (2009) Retrospective study of 19 patients with intramedullary spinal cord metastasis. *Clin Neurol Neurosurg* 111: 10-17.
- 26 Payer S, Mende KC, Westphal M, Eicker SO (2015) Intramedullary spinal cord metastases: an increasingly common diagnosis. *Neurosurg Focus*. 39: E15.
- 27 Pellegrini D, Quezel MA, Bruetman JE (2009) Intramedullary spinal cord metastasis. *Arch Neurol* 66: 1422.